

# Safety and Efficacy of Trans-Ulnar Coronary Intervention

AHM Waliul Islam, Azfar H. Bhuiyan, Shams Munwar, Nighat Islam, Atique bin Siddique, Intekhab Yousuf, Tamzeed Ahmed, Sahabuddin Talukder, AQM Reza, M S Alam,  
*Dept. of Invasive and Interventional Cardiology, Apollo Hospitals, Dhaka*

### Abstract:

#### Keywords:

Ischaemic heart disease, Coronary angiogram, angioplasty, Ulnar artery, Radial artery.

**Background:** Primary aim of our study to evaluate the safety and feasibility of percutaneous Trans-Ulnar approach for coronary angiogram and intervention.

**Methods:** Patient whom radial pulse was very feeble and difficult to cannulate and having very good volume Ulnar pulse were selected in this study. Total 48 (Male 37: Female 11) patients were enrolled in this very preliminary study who underwent elective coronary angiogram (CAG) and subsequent adhoc percutaneous coronary intervention (PCI) in same sitting. Total 11 stents were deployed in 10 territories. Mean ages of male and female were 59 and 52 years respectively. Associated coronary artery disease (CAD) risk factors were dyslipidemia, high blood pressure, diabetes mellitus, positive family history of CAD and smoking (all male).

**Results:** Among the study group; 36(75%) were Dyslipidemic, 35(73%) were hypertensive; 34(70.1%) patients were Diabetic, FH 11(23%), and 12(25%) were all male smoker. PCI performed in 9 patients i.e., 18.8% of the total population of this study. Angiographic diagnosis of TVD 8(16.6%), DVD 6(25%), SVD 17 (35.4%), Normal Coronaries 8(16.6%), ISR or patent stent 5(10.4%), Severe Calcified disease 4(12%). Common stented territory was LAD 6(66%), LCX 2(22%) and RCA 2 (22%). Vaso-spasm was not noted as it is quite often in trans-radial approach. Procedural complication like hematoma was not present.

**Conclusion:** We conclude that trans-ulnar approach is a safe, feasible and effective alternative to Trans-femoral and Trans-radial approach, specially due to sluggish flow or feeble radial pulsation with severe spasm of radial artery for coronary angiogram and subsequent PCI.

(*Cardiovasc. j.* 2018; 11(1): 5-9)

### Introduction:

Cardiovascular disease remains the most common disease, worldwide, in individuals older than 50 years. Among these many needs invasive procedures to investigate or to treat coronary artery disease. Since the first human heart catheterization by Werner Forssman in 1929, access site approach has gone considerable evolution and technical refinement.<sup>1</sup> Femoral artery puncture and sheath insertion by modified Sheldinger technique evolved into the standard method of invasive cardiovascular procedure.<sup>2</sup>

Percutaneous Transradial approach for diagnostics CAG was first described by Lucien Campeau<sup>3</sup> in 1989 and the first effective PCI via transradial (TRA) was performed in 1993 by Ferdinand Kiemeneji.<sup>4</sup> Transfemoral and

Transradial approaches are safe and effective ways to perform intervention.<sup>3-5</sup> However, access-site complications after diagnostic and interventional procedures are major concern in the field of interventional cardiology. Transulnar cannulation has been described as an interesting alternative approach for diagnostics and therapeutics procedures.<sup>6</sup>

Beyond the proven benefits, regarding patient comfort and reduced hospitalization time; trans-radial approach has an established role as a bleeding avoidance strategy among patients undergoing invasive coronary procedures. Unsuccessful radial artery puncture, inability to advance the guide catheter and inadequate support are the key mainstay of its failure. Among dedicated radialist, crossover rate is 2%

and complete occlusion may occur up to 5% patient at discharge.<sup>7</sup>

Andrade et al. has shown that transulnar approach as an alternative access site for coronary invasive procedures after transradial approach failure.<sup>8</sup>

Therefore, we designed to evaluate the safety and feasibility of the percutaneous ulnar approach for CAG and PCI in our population, whose radial cannulation was failed due to very feeble or sluggish radial pulsation or severe spasm.

## Methods:

### *Study Population:*

From June 2016 to December 2017, total 48 patients (Male 37: Female 11) were selected for the study, whom transradial artery cannulation failed due very feeble radial pulse, tortuous courses and /or failed to negotiate catheter due to vaso-spasm. Written consent was taken from patient as well as the first degree relative. Patients were eligible for transulnar intervention if they have good volume palpable ulnar pulse and a positive reverse Allen's test (<10 Sec). These criteria were used to ensure proper blood supply to the hand from the radial artery.

### *Ulnar Cannulation and procedure:*

All procedure was performed by expert operator who has experiences of more than 1000 transradial interventions. Patients were positioned in supine position with arms along the body side abducted to approximately 70 degrees. Through hyperextension of the wrist and infiltration of skin by giving LA (1-2ml Lidocaine, 2%), the ulnar artery was punctured at 1-3 cm proximal to the Pisiform bone over the palpable and most powerful pulsation ulnar artery, with a puncture angle of 45 degrees, using Terumo puncture needle by Sheldinger technique. The Ulnar artery was punctured with Terumo needle. After a small skin incision, a 5F or 6F Terumo Radial sheath) was introduced.

Vasodilator drug (Nitroglycerine), a bolus of heparin (2000 IU) for diagnostic CAG and addition 5000 IU for PCI were given. For diagnostic CAG we used Terumo Radial angiography catheter and Xtra back up guide catheter for LCA angioplasty and Right Judkins for RCA coronary intervention. The sheath was removed immediately after the procedure and hemostasis was achieved with

compressive dressing applied. Four hour later the compressive dressing removed, patient was discharged on same day those who had CAG only and third day those who had PCI. Clinical examinations of the puncture site and evaluation of the ulnar pulse were performed at the time of hospital discharge, 2-3 hours after diagnostic procedures, all the morning following completion of therapeutic procedure. Patients were clinically examined, one week after discharge. The evaluation included radial and ulnar pulse palpation and a reverse Allen's Test to evaluate blood supply to the hand

### *Drug Therapy*

All the patients received Aspirin 300 mg and Clopidogrol as a loading dose 300 mg prior to CAG and PCI with or without Ticagrelor or Prasugogrel. and continued for 9-12 months and received atorvastatin along with standard medical management for CAD. During the procedure, an intravenous heparin bolus (100IU/Kg) and GP IIb/IIIa receptor blocker Integrillin were administered as required. The use of GP IIb/IIIa Receptor blocker was recommended as per protocol.

Data: Data were presented as mean  $\pm$  SD with percentage.

## Results:

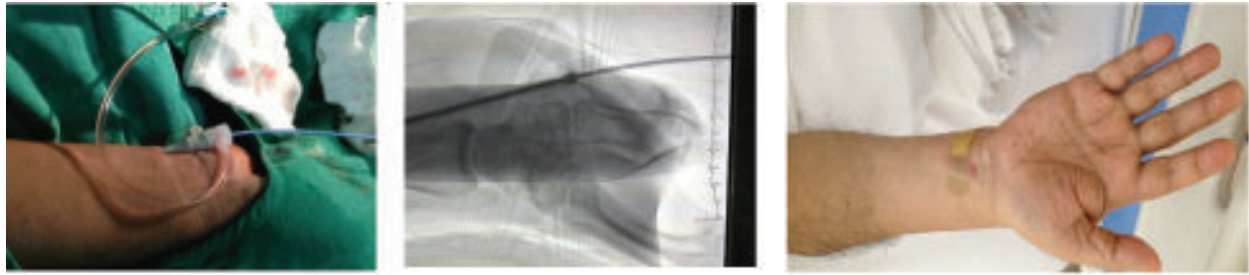
Table I. shows demographic profile of Studied population. Male were older than female. Female were more obese than male and poorly controlled diabetes.

**Table-I**  
*Demographic Profile of patient.*

	Male	Female
Number	39	9
Age (yrs)	58.2 $\pm$ 9.9	53.6 $\pm$ 8.9
BMI(kg/m <sup>2</sup> )	26.7 $\pm$ 3.2	27.6 $\pm$ 3.9
SBP(mmHg)	132 $\pm$ 14	138 $\pm$ 15
DBP(mmHg)	80 $\pm$ 6.7	79 $\pm$ 8.3
Risk Factor	2.0 $\pm$ 0.7	1.5 $\pm$ 0.5
RBS(mmol/L)	7.9 $\pm$ 1.8	10 $\pm$ 2.7
Fluoro time	111.8 $\pm$ 31.1	123.8 $\pm$ 23.9
Fluoro Dose	386 $\pm$ 184.4	397.8 $\pm$ 114.1

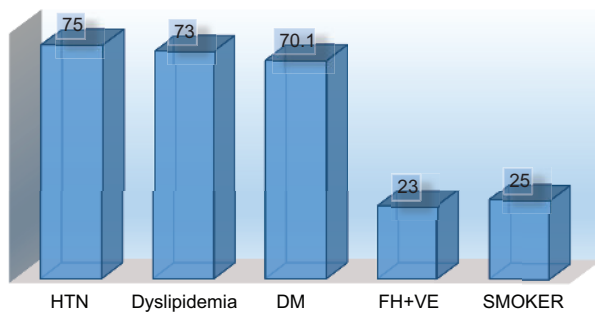
*Data were presented as Mean  $\pm$  SD*

Fig 1 shows the radiological images of ulnar approach and Fig 2 shows the distribution of CAD risk factors. Among the studied population;



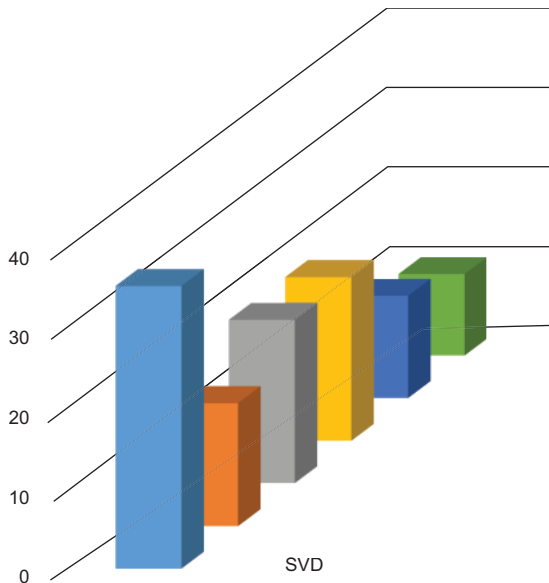
**Fig.-1:** Showing the radiographic images of access site Ulnar approach.

36(75%) were Dyslipidemia, 35(73%) were hypertensive; 34(70.1%) patients were Diabetic, FH 11(23%), and 12(25%) were all male smoker.



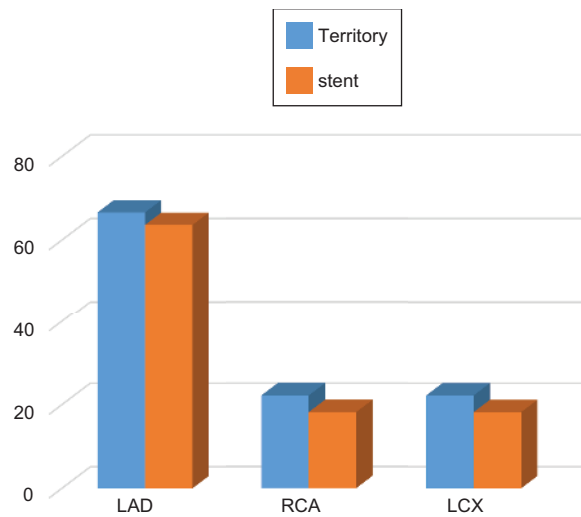
**Fig.-2:** Percentage of Distribution of CAD Risk Factors.

Fig 3. shows the angiographic diagnosis. Among them; Angiographic diagnosis of TVD 8(16.6%), DVD 6(25%), SVD 17 (35.4%), Normal Coronaries 8(16.6%), ISR or patent stent 5(10.4%), Severe



**Fig.-3:** Percentage distribution of Angiographic Diagnosis.

Calcified disease 4(12%). Fig 4. shows the distribution of coronary territory and stents. Common stented territory was LAD 6(66%), LCX 2(22%) and RCA 2 (22%).



**Fig.-4:** Percentage of distribution of Coronary territory and stents.

**Discussion:**

This is a very preliminary study in our center to use ulnar artery approach site for invasive and interventional procedure. We performed transulnar procedure when we failed to cannulate Radial artery due to difficult or anomalous radial courses or access through transradial artery is very difficult due to significant radial artery (RA) abnormalities, severe loops and curvatures, tortuous course, hyoplastic RA, after failed RA puncture and repeated uses of the RA.

Beyond the proven benefits regarding patient comfort and reduced hospitalization time, the transradial approach has an established role as a bleeding avoidance strategy among patient

undergoing invasive coronary procedures.<sup>7</sup> However, unsuccessful radial artery puncture, inability to advance the guide catheter to ascending aorta, inadequate guide catheter support represents mechanism of transradial approach failure. Even among dedicated radialist, the crossover rate can reach more than 2%. Radial artery occlusion may occur in 5% of patients at hospital discharge, preventing its reuse in future procedures.<sup>9</sup>

Transulnar approach has been proposed as an alternative access of intervention in patients not suitable for TRA. With the rationale of sharing same efficacy and safety promoted by radial access, it can be easily performed by operators familiar with the transradial approach.<sup>10,11</sup>

Ulnar artery(UA), generally has got a larger diameter than radial artery(RA), (UA/RA ratio= 1.35) and a straighter course than that of radial artery. It is more deeply seated. Procedural success, advantages and complication rates are similar to those of transradial artery. Entry site complications were less frequent, with no significant hematoma or need for blood transfusion. Trauma to ulnar nerve can be avoided by careful placement of small gage needle. Else, has described it is safe approach as the radial with fewer vascular complication.<sup>12</sup> Ulnar artery has a larger diameter and fewer alpha-receptor than radial artery. As a result, chances of vasospasm is lower in transulnar Artery than transradial Artery, since vasospasm is related to vessel size and is mediated by alpha-receptors response to epinephrine.<sup>13,14</sup> incidents of spasm are not easily quantified, but they may be estimated by pain and by difficulty in handling wire and or catheter manipulation.

The incidence of acute or chronic ischemic complications related to the occlusion of ulnar artery is virtually absent.<sup>15</sup> The hand presents a dual blood supply formed by the Ulnar artery, which originates the superficial palmar arch (found in 40-80% cases), and by the radial artery, which originates the deep palmar arch (found in 95% cases).

Transradial or Transulnar approach improves patient comfort and satisfaction, allows rapid

mobilization, and is associated with reduced procedural cost and hospital stay. Same-day home discharge of CAG patient and day three for PCI patients without any noticeable procedure related complications, transulnar may become the new gold standard approach of coronary intervention.

Therefore, we may conclude that the coronary intervention through Trans-Ulnar approach is safe and effective alternative to femoral and radial approach. Moreover, it will preserve the femoral artery integrity for access with large devices for eventual valve implantation or endovascular procedures

Moreover, our experience at apollo hospital, Transulnar approach coronary intervention is an effective, safe and alternative to transradial and femoral approach.

The incidence of acute or chronic ischemic complications related to ulnar artery occlusion after the performance of coronary procedure is rare,<sup>16</sup> due to dual blood supply of the circulation of hand.<sup>9</sup> Previously ulnar artery uses was not encouraged in patients with failed procedure through ipsilateral radial artery.<sup>17</sup>

In addition to conventional transfemoral, transradial, transulnar approach is being used by some of the operator. In addition, now a day, many have started access site approach through anatomical snuff box (distal radial). There might be several route to access to coronary, no matter what individual operator like to choose, the things need to be care about, is to do the things perfectly and patient comfort and safety must be warranted.

#### **Conclusion:**

We may conclude that access site approach to perform coronary angiogram and percutaneous coronary intervention by transulnar route is safe and effective alternative to transfemoral and transradial approach. Operator, need to be skilled enough with Femoral and Radial route, before to swap to Ulnar or Snuff box.

---

#### **Conflict of Interest - None.**

---

#### **References:**

1. Sashko K, et al. Transradial and transulnar access for percutaneous coronary interventions. *Arch Turk Society Cardiol* 2011; 39(4): 332-340.

2. Seldinger SI. Catheter replacement of the needle in percutaneous arteriography. A new technique. *Acta Radiol* 1953; 39:368-376.
3. Campea L. Percutaneous radial artery approach for coronary angiography. *Cathet Cardiovasc Diagn* 1989; 16:3-7.
4. Kiemeneij F, Laarman GJ. Percutaneous radial artery approach for coronary stent implantation. *Cathet Cardiovasc Diagn* 1993; 30:173-178.
5. Bourassa MG, Noble J. Complication rate of coronary arteriography. A review of 5250 cases studied by a percutaneous femoral technique. *Circulation* 1976; 53(1): 106-114.
6. Dashkoff N, Dashkoff PB, Zizzi ZA, et al. Ulnar artery cannulation for coronary angiography and percutaneous coronary intervention: case report and anatomic considerations. *Catheter Cardiovasc Interv* 2002; 55(1): 93-96.
7. Subherwal S, Peterson ED, Doi D, et al. Temporal trends in and factors associated with bleeding complications among patient undergoing percutaneous coronary intervention: a report from national cardiovascular data Cath PCI Registry. *J Am Col Cardiol* 2012; 59:1861-1869.
8. De Andrade Pedro Beraldo, Andre Tebet Marden, Nogueira Ederlon Ferreira, et al. that transulnar approach as an alternative access site for coronary invasive procedures after transradial approach failure. *Am Heart J* 2012; 164: 462-467.
9. Stella PR, Kiemeneij F, Laarman GJ, et al. Incidence and outcome of radial artery occlusion following transradial artery coronary angioplasty. *Cath Cardiovasc Diagn* 1997; 40:156-158.
10. Mehran R, Rao SV, Bhatt DL, et al. Standardized bleeding definitions for cardiovascular clinical trials: a consensus report from the Bleeding Academic Research Consortium. *Circulation* 2011; 123:2736-2747.
11. Limbruno U, Rossini R, De Carlo M, et al. Percutaneous ulnar artery approach for primary angioplasty: safety and feasibility. *Cath Cardiovasc Interv* 2004; 61:56-59.
12. Mangin L, Bertrand OF, De La Rochelliere R, et al. The trans-ulnar approach for coronary intervention: a safe alternative to trans-radial approach in selected patients. *J Invasive Cardiol* 2005; 17(2): 77-79.
13. Kiemeneij F. Prevention and management of radial artery spasm. *J Invasive Cardiol* 2006; 18(4): 159-160.
14. Fukuda N, Iwahara S, Harada A, et al. Vasospasm of radial artery after the transradial approach for coronary angiography and angioplasty. *Jpn Heart J* 2004 ; 45 (5): 723-731.
15. Terashima M, Meguro T, Takeda H, et al. Percutaneous ulnar artery approach for coronary angiography: A preliminary report in nine patients. *Cath Cardiovasc Interv* 2001; 53:410-414.
16. Roberts EB, Palmer N, Perry RA, et al. Trans Ulnar access for coronary angiography and intervention: an early guide research and clinical practice. *J Invasive Cardiol* 2007; 19:83-87.
17. Aptekar E, Dupouy P, Chabane Chaouch M, et al. Percutaneous transulnar artery approach for diagnostic and therapeutic coronary intervention. *J Invasive Cardiol* 2005; 17:312-317.