

Patency of Multiple stents/Overlapping Stents in Single Artery Territory in Bangladeshi Patient: An Updated Single Center Experiences

S Munwar, AHMW. Islam, S Talukder, AQM Reza, T Ahmed, A H Bhuiyan, R Masud, AB Siddique, SR Shohel, S Alam, A Miah, A Karim

Dept of Interventional and Invasive cardiology, Apollo Hospitals Dhaka, Bangladesh

Abstract:

Keywords:
Stent, PCI,
Coronary artery
disease.

Background: Coronary artery disease (CAD) in Bangladeshi population is diffuse in nature with small caliber arteries. Now a day, these are treated, by PCI with stent deployment, often multiple in a single coronary artery. However, long term data on In-stent re-stenosis (ISR) in multiple or overlapping stent in single coronary artery in these patients is not yet available. Therefore, the aim of our present study was to assess long-term outcome of stent patency or the development of ISR of varieties stent in single vessel territory.

Methods: Patients were prospectively selected from, who underwent coronary angiogram at our hospital for further evaluation of their previous PTCA in the 3-36 months preceding the study for the quantifying period of 2007-2011. Total 51 patients (male: 42, Female: 9) who had multiple stents in one coronary artery were included in this study. Average age was Male: 57; Female:61. Average study period was 3.1 ± 2.4yrs.

Results: Our results show that, among the total studied population 82.4% (42) were male and 17.6% (9) were female. Total 114 stent were deployed in 54 vessels of 51 patients. Territory wise distribution of deployed stent was LAD 52(45.6%), RCA 42 (36.8%) and LCX 20(17.5%). Stent used were BMS 45(39.5%), DES 69(60.5%). Re-look Coronary Angiogram (CAG) revealed that Significant ISR (ISR>60%) developed in BMS 8(17.8%) and DES 8(11.5%). Among the different DES the development of significant ISR were in Sirolimus 1(3.2%), Paclitaxel 4(16%), Everolimus 3 (30%).

Conclusion: Our study has shown that deployment of multiple stents in a single artery territory (either separately or as overlapping) is safe and has reasonably lower degree of ISR, even when BMS was used. As a whole BMS shows higher degree of ISR than to DES for an average period of follow up of 3.1 yrs.

(*Cardiovasc. j.* 2013; 5(2): 154-159)

Introduction:

It has been well known that the nature of CAD in Bangladeshi patient population is diffuse in nature and of small in caliber.¹⁻³ Stent implantation has become the treatment of choice among patients with CAD.^{4,5} Data on overlapping stent in our population is not well studied. In-stent restenosis (ISR) remains a major limitation to the long term success of coronary angioplasty. Dependent on various confounding cofactors, such as the presence or absence of diabetes mellitus, target vessel size and lesion length and the degree of vessel patency achieved by intervention, Restenosis at the site of stent implantation is seen in 15-60% patients.⁶⁻⁸ Neointimal hyperplasia as a response to vessel-wall injury has been identified as the mechanism

of ISR.⁹ DES have dramatically reduced the rates of restenosis and target lesion revascularization compared to bare metal stents.¹⁰ The role of stent overlap as an independent determinant of restenosis is unclear. Implantation of Multiple >2 overlapping coronary stents has been reported in as many as 30% of patients undergoing Percutaneous coronary interventions owing to excessive target lesion length, incomplete lesion coverage and or endothelial injury requiring additional stents scaffolding beyond the margins of the initial stent deployed.¹¹⁻¹³ Implantation of multiple overlapping stents may be associated with a greater late lumen loss and more frequent angiographic restenosis regardless of stent type.¹⁴ Therefore, the aim of our present study was to assess the impact of Multiple/overlapping

Correspondence and Reprint request: Dr. A H M Waliul Islam, Department of Interventional and Invasive Cardiology, Apollo Hospitals Dhaka, Bangladesh. e-mail: ahmwislam@apollodhaka.com

stent in the development ISR in our population subsets.

Methods:

Patients were selected from those who underwent routine coronary angiogram for further evaluation of their coronary status. Most of the patient population in this study had percutaneous coronary intervention (PCI) either with bare metal stent or drug eluting stent in the preceding 3-36 months. Eligible patients had a history of stable or unstable angina or documented / silent myocardial infarction. The target lesion for study was an in-stent coronary arterial lesion between 15 mm and 40 mm with 2.5-4.0 mm in diameter. No exclusion criteria adopted because of the small sample size.

Procedure: CAG was performed as per standard protocol. Individual discretion was applied as per operator’s choice, depending on patient’s problem. Details of the previous procedure were collected from patient’s old papers. These included indication, stent detail, complication etc. Whenever possible, old angiogram was also reviewed and compared to the current cine angiogram. ISR was defined by visual / eyeball estimation by two experts. Edge re-stenosis was defined as greater than 50% narrowing in the 5mm immediate or distal to the treated region. ISR of significance was also defined as >50% was of lumen inside the stent. Data were presented as mean ± SD with percentage.

Results:

Our results show that, 12.5%(51) patient out of total 408 patients, has multiple stent in single coronary territory were included in this study. Average age was Male: 57; Female:61. Among the studied population 42 were Male and 98 were female. **Table I.** showing the profile and clinical data of studied population. Female are older than male (male 57.2 ± 12.4 vs female: 61 ± 12.4) and obese as male(BMI in male: 26.0 ± 4.1 vs female 26.0 ± 4.1). Systolic BP were higher in male than female (Male: Female SBP: 136 ± 14.9 vs 126.0 ± 14.9 ; DBP: 78.5 ± 7.5 vs 78.4 ± 7.5). Average number of CAD risk factors was higher in male than female (2.83 ± 0.7 : 2.5 ± 0.7). Average duration the development of ISR was 3.1 ± 2.4 yrs

Table-I
Demographic Profile of patient

	Male	Female
Number	42	9
Age (yrs)	57.2±12.4	61±12.4
BMI(kg/m ²)	26.0±4.1	26.0±4.1
SBP(mmHg)	136±14.9	126±14.9
DBP(mmHg)	78.5±7.5	78.4±7.5
No of Risk Factor	2.83±0.7	2.56±0.73
RBS(mmol/L)	6.63±1.2	12.9±7.45

Table II, showing the average length of the stent (in LAD: 43.5 ± 11.4 ; LCX: 42.9 ± 15.9 ; RCA 49.5 ± 16.7) and diameter (LAD 2.98 ± 0.3 LCX 2.7 ± 0.3 ; RCA: 3.1 ± 0.3 .) and stent deployment pressure were LAD: 13.8 ± 1.4 , LCX: 13.6 ± 1.9 , RCA: 14.0 ± 1.5 .

Table-II
Average size of Stent used with inflation pressure

	Length (mm)	Diameter (mm)	Inflation Pressure(ATM)
LAD	43.5±11.4	2.98±0.3	13.8±1.4
LCX	42.9±15.9	2.7±0.3	13.6±1.9
RCA	49.5±16.7	3.1±0.3	14.0±1.5

Fig. 1 showing the coronary artery territory wise percentage distribution of stent used; it’s patency and subsequent development of ISR. LAD and LCX has reduced ISR development.

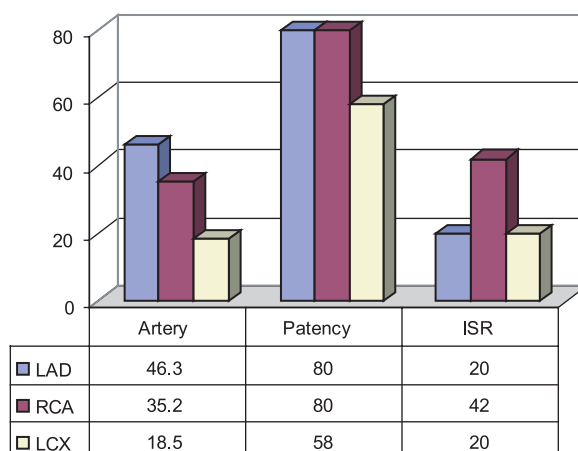


Fig.-1. Percentage Distribution of Stented artery, it’s patency and ISR Development

Fig 2. Showing that Dyslipidemia is the predominant risk factors in 43 (84.3%) patients followed by HTN in 35(68.6%), DM in 30 (58.8%), positive FH in 11 (21.6%) and smoker in 18 (31.4%) patients (all male). Total 114 stent were deployed in 54 vessels of 51 patients.

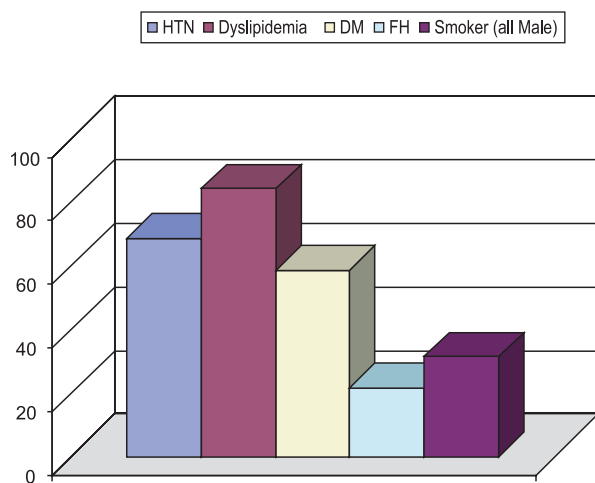


Fig.-2: Percentage of distribution of CAD Risk Factors

Fig. 3 showing percentage distribution of different stent used and its subsequent ISR development. Among the different DES the development of significant ISR were in Sirolimus 1(3.2%), Paclitaxel 4(16%), and Everolimus 3 (30%).

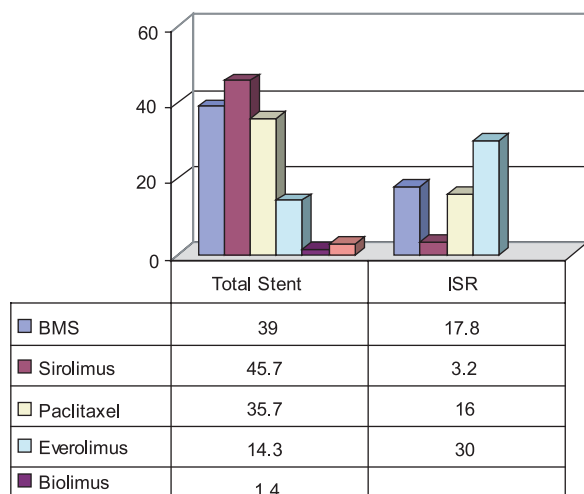


Fig.-3. Percentage of Distribution of Types of Stent used and subsequent ISR Development

Fig 4. Shows the percentage distribution of BMS and DES used with reduced ISR in DES treated patient. ISR (ISR>60%) developed in BMS 18.2% and DES 11.4%.

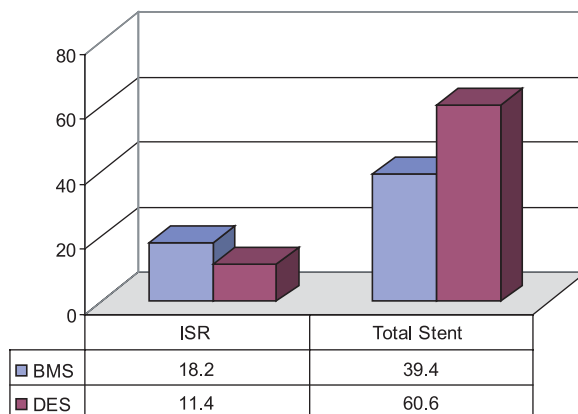


Fig.-4: Percentage Distribution of Total Stent and development of ISR

Fig.5 shows the common stented territory were LAD 45.6%, LCX 17.5% and RCA 36.8%.

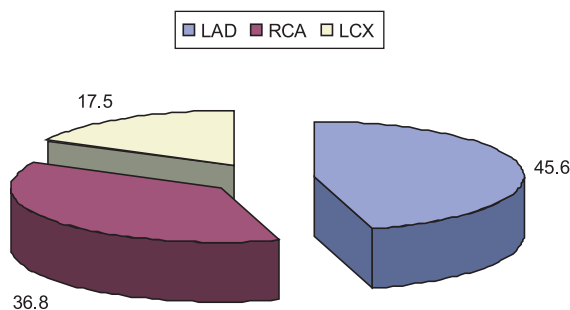


Fig.-5: Percentage Distribution of Common Stented Territory

Discussion:

Previously, we for the first time published the stent patency and the development subsequent ISR in Bangladeshi patient population.¹⁵ Since, we don't have any data in our patient perspective on the overlapping / multiple stents in a single vessel territory. Therefore, we have carried out this non-randomized prospective cohort to see which stent is better or have reduced ISR development.

With the advances of patient management, patients with Acute Myocardial Infarction (AMI) or Acute Coronary Syndrome (ACS), PCI by using

bare metal stent (BMS) reduces the acute closure or late restenosis 30-50% compared with balloon angioplasty alone, has already established.¹⁶⁻¹⁷ With the property of site specific anti-proliferating drug delivery system by drug eluting stent (DES) reduces the clinical and angiographic restenosis by <10% by inhibiting neointimal hyperplasia.¹⁸⁻¹⁹ Restenosis after angioplasty and stent implantation has been historically considered the most significant problem in coronary interventional treatment.²⁰ Neointimal hyperplasia has been identified as underlying mechanism of development of ISR.⁹ The implantation of multiple/overlapping stents may be prompted by excessive target lesion length, incomplete lesion coverage and or endothelial injury requiring additional stents scaffolding beyond the margins of the initial stent deployed.¹⁴ Furthermore, multiple overlapping stents may be required to repair extensive spiral coronary dissection. Stent strut overlap has been incriminated both as stimulus to neointimal hyperplasia and to late angiographic restenosis.²¹⁻²³ Implantation of multiple stents presents technical challenges in delivery and alignment to insure adequate stent overlap and lesion coverage. Stent overlap is associated with neointimal proliferation and subsequent late lumen loss regardless of stent type. Deliberate stent overlap is a recognized option for the treatment of in-stent restenosis for both bare metal and drug eluting stent.²⁴ Maximal lumen narrowing occurs at the sites of DES overlap in majority of patient with increased drugs and polymer concentration. Theoretical concerns related to the use of overlapping drug-eluting stents include potential toxic effect of 'double' doses of a drug on the vascular wall which may result in positive remodeling, aneurysm formation and possible stent thrombosis. As well as aggravated restenosis as a consequence of increased implantation injury and delayed healing; potential adverse reaction to a polymer delivery system in terms of inflammation and thrombogenic effects may also increase with overlapping stent.^{25,26}

However, the relative contribution of target lesion length, total stented segment and number of deployed stent per target lesion toward the occurrence of periprocedural MACE and or late angiographic stenosis is debatable.^{7,8, 28}

Keriakes shown that 1st generation Drug eluting stent (DES) Sirolimus-eluting stent is safe, efficacious in reducing restenosis with no increase in the incidence of MI compare to BMS.¹⁴ On the contrary, 2nd generation Everolimus eluting stent (EES) compared with Paclitaxel eluting stent (PES) provided significant improvements in clinical safety and efficacy.²⁷ Possible explanation of 1st generation is because of thick strut and high metal contents impair deliverability, increase stent mediated vascular injury, the 2nd generation DES has thin strut cobalt chromium platform with less metal content easy to deliver with flexibility and less vascular injury.

In our present study we found that female are more obese and developed CAD in more advance age than male patients. Admission BP was higher in male either due to obesity or from non-compliance to their current medication. We also found that average number of CAD risk factors were higher in male than female, although male are having one more exclusive CAD risk factors as being smoker. Among the CAD risk factors dyslipidemia contributed an important role in the development of atherosclerotic CAD followed by HTN, DM and positive FH and smoking (all male patients). We found, Sirolimus-eluting stent has reduced ISR than other limus and Paclitaxel-eluting stent. LAD and LCX artery shows increase patency with reduced ISR development, whether RCA has less patency with increased ISR. Stent under sizing and or inappropriate inflation during deployment could be one of the possible reasons of increased ISR in RCA. In addition use of IVUS support, these issues could have been addressed.

Tsagalou et al,²⁹ has shown that the implantation of multiple overlapping DES in patients with diffuse LAD is relatively safe and associated with good midterm clinical outcomes. In female, obesity and advanced age with other comorbidities might have important role in the development of ISR in these sub population. On the contrary, male patient with higher BP and smoking in addition to other comorbidities might have important role in the development of ISR.

Although, exact etiology of ISR is not yet established in the context to our population, but genetic predominance, family inheritance, smoking, diabetes, HTN and Dyslipidemia are well known contributory risk factors in developing CAD as well ISR in the western world and in our population. In addition, lack of follow-up after PCI in the same center, health ignorance, financial insolvency, sedentary life styles does plays key role in these patients for development of ISR.

In our present study, we found that the Sirolimus eluting stent (SES) multiple overlapping stent has reduced ISR than other DES and BMS in this prospective cohort of Bangladeshi patient. Stent based polymer elution of Sirolimus is effective in suppressing neointimal hyperplasia. On the other hand other limus is not sufficient in number to conclude its superiority or not inferior than SES in our population, because of small number of patients. We have carried out this prospective cohort, and demonstrated for the first time that ISR is less in Sirolimus-eluting stent in multiple/overlapping stent uses

Conclusion:

Overlapping stents in a single coronary artery lesion carries a risk of restenosis. Several studies have shown the promising result of different DES. Among them, many has shown potential better outcome with reduced ISR in Sirolimus eluting stent and non-inferior results by 2nd generation EES DES. It is difficult to conclude in this present prospective cohort which DES is better in our patient perspective. We need more data and multicenter registry in Bangladesh in addition to statistical significance. Because of the small number, we could not able to do the comparative study between BMS with DES or between 1st and 2nd generation DES. In this regards, our future plan is to enroll more patient and involve more center and to find out which DES is appropriate in reducing angiographic restenosis in overlapping segment if possible to do randomize comparative study.

Limitation: Most of our studied patients had their PCI done either with BMS or DES in other centers. We had to depend on the reports provided by the patients. Although they all

included stent details, procedural details were missing. We eventually got only information about the type of stent used and few other details.

Conflict of Interest - None.

References:

1. AR khan, AS Majumder et al. Study of lipid profile and coronary angiographic pattern in young Bangladeshi patient with acute coronary syndrome. *Cardiovasc. j* 2009;1(2):183-188.
2. MA Hussain, A Nahar, S Ara et al. The dominance pattern of Coronary artery of adult Bangladeshi people-A postmortem morphological study. *Cardiovasc. j* 2008;1(1):21-25.
3. PM McKeigue. Coronary heart disease in Indians, Pakistanis and Bangladeshi; Aetiology and possibilities for prevention. *Br Heart J* 1992;62(5):341-342.
4. Serruys PW, de jaegre P, Kiemeneji F. A comparison of balloon expandable stent implantation with balloon angioplasty in patients with coronary artery disease. *N Eng J Med* 1994;331:489- 495.
5. Fischhman DL, Leon MB, Baim DS. A randomized comparison of coronary stent placement and balloon angioplasty in the treatment of coronary artery disease. *N Eng J Med* 1994;331:496-501.
6. Serruys PW, Van Hout B, Bonnier H. Randomized comparison of implantation of heparin-coated stents with balloon angioplasty in selected patients with coronary artery disease. (Benstent II). *Lancet* 1998; 352:673-681.
7. Kastrati A, Schomig A, Elezi S. Predictive factors of restenosis after coronary stent placement. *J Am Coll Cardiol* 1997; 36:1428-1436.
8. Bauter C, Hubert E, Prat A. Predictors of restenosis after coronary stent implantation. *J Am Coll Cardiol* 1998; 31:1291-1298.
9. Hoffman R, Herrmann G, Silber S. Randomized comparison of success and adverse event rates and cost effectiveness of one long versus two short stents for treatment of long coronary narrowing. *Am J Cardiol* 2002; 90:460-464.
10. Stettler C, Wandel S, Allemann S. Outcomes associated with drug eluting and bare metal stents: a collaborative network meta-analysis. *Lancet* 2007;370:937-948.
11. Kastrati A, Elezi S, Dirschinger J et al. Influence of lesion length on restenosis after coronary stent placement. *Am J Cardiol* 1999;83:1617-1622.
12. Stone GW, Ellis SG, Cox DA et al. One year clinical results with the slow-release polymer based Paclitaxel-eluting stent: the TAXUS IV trial. *Circulation* 2004; 109: 1942-1947.
13. Schampaert E, Moses JW, Schofer J et al. Sirolimus – eluting stents at two years: a pooled analysis with

- emphasis on late revascularizations and stent thrombosis. *Am J Cardiol* 2006; 98:36-41.
14. Kereiakes DJ, Wang H, Pompa JJ. Periprocedural and late complication of overlapping Cypher Sirolimus-eluting stent. *J Am Coll Cardiol* 2006; 48:21-31.
 15. Shams Munwar, AHM Waliul Islam et al. Study of in-stent Restenosis (ISR) in patient with Coronary Artery Disease (CAD): Primary survival outcome, etiology of stent occlusion and future prospect in Bangladesh stent era. *Bangladesh Heart Journal* 2008; 23(1):18-23.
 16. Suttorp MJ, Laarman GJ, Rahel BM. Primary stenting of totally occluded native coronary arteries II (PRISON II) study: A randomized comparison of bare metal stent implantation with Sirolimus-eluting stent implantation for the treatment of total coronary occlusion. *Circulation* 2006; 114:921-928.
 17. Lei Ge, Lakovou L, Cosgrave J et al. Immediate and mid-term outcomes of Sirolimus-eluting stent implantation for chronic total occlusions. *Eur Heart J* 2005; 26:1056-1062.
 18. Serruys PW, de Jaegere P, Kiemenweji F et al. A comparison of balloon expandable stent implantation with balloon angioplasty in patients with coronary artery disease. *N Eng J Med* 1994; 331:489-495.
 19. Fischman DL, Leon MB, Baim DS et al. A randomized comparison of coronary stent placement and balloon angioplasty in the treatment of coronary artery disease. *N Eng J Med* 1994; 331:496-501.
 20. Dangas G, Fuster V. Management of restenosis after coronary intervention. *Am Heart J* 1996; 131:428-36
 21. Ellis SG, Savage M, Fischman D. Restenosis after implantation of Palmaz-Schatz stents in native coronary arteries. *Circulation* 1992; 86:1836-1844.
 22. Kastrati A, Elezi S, Dirschinger J. Influence of lesion length on restenosis after coronary stent placement. *Am J Cardiol* 1999; 83:1617-1622.
 23. Haude M, Erbel R, Straub U. Short and long term results after intracoronary stenting in human coronary arteries: monocenter experiences with balloon expandable Palmaz-Schatz stent. *Br Heart J* 1991; 66:337-345.
 24. Tanabe E, Serruys PW, Grube E. Taxus III trial: in-stent restenosis treated with stent-based delivery of Paclitaxel incorporated in a slow-release polymer formulation. *Circulation* 2003; 107:559-564.
 25. Finn AV, Kolodgie FD, Harnek J et al. Differential response of delayed healing and persistence inflammation at sites of overlapping Sirolimus- or Paclitaxel-eluting stents. *Circulation* 2005; 112:270-278.
 26. Van der Giessen WJ, Lincoff AM, Schwartz RS et al. Marked inflammatory sequel to implantation of biodegradable and non biodegradable polymers in porcine coronary arteries. *Circulation* 1996; 94:1690-1697.
 27. Kereiakes DJ, Krishnankutty S, Hermiller JB. Comparison of Everolimus-eluting stents in patients undergoing multilesion and multi-vessel intervention. *J Am Coll Cardiol*; 2010; 3:1229-1239.
 28. Kornowowski R, Mehran R, Hong MK. Procedural results and late clinical outcomes after placement of three or more stents in single coronary artery. *Circulation* 1998; 97:1355-1361.
 29. Tsagalou E, Chieffo A, Iakovou I. Multiple overlapping stents to treat diffuse disease of the left anterior descending artery. *J Am Coll Cardiol* 2005; 45:1570-1573.