

# Percutaneous Balloon Aortic Valvuloplasty (Pbav) in a Child With Congenital Severe Aortic Stenosis –A Case Report

AQM Reza, MSR Patwary , A Baqui  
Department of Cardiology, NICVD

## Abstract:

**Key Words:**  
Percutaneous balloon aortic valvuloplasty, Severe aortic stenosis, Bicuspid aortic valve

A 8 years old boy presented with shortness of breath, cough and palpitation and subsequently diagnosed as a case of severe aortic stenosis with bicuspid aortic valve. Percutaneous balloon aortic valvuloplasty (PBAV) was done and he became asymptomatic. Post procedure his aortic valve area and aortic systolic pressure increased, transaortic pressure gradient decreased. So good result, lower cost, elimination of drawbacks of thoracotomy and cardiopulmonary bypass suggest in children percutaneous balloon aortic valvuloplasty should be the treatment of choice for patients with severe aortic stenosis.

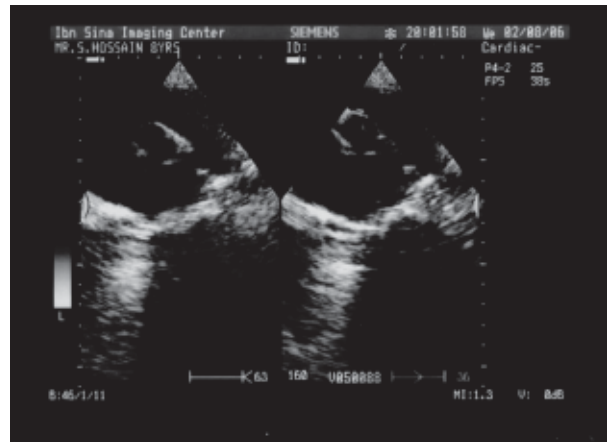(Cardiovasc. j. 2009; 1(2) : 234-236)

## Introduction:

Valvular aortic stenosis accounts for approximately 4% to 6% of all cases of congenital heart disease.<sup>1</sup> Percutaneous balloon valvuloplasty was first described in 1984 for treatment of congenital valvular aortic stenosis in children.<sup>2</sup> Most congenital stenotic aortic valves are bicuspid, progressive disease with a single central or eccentric commissure and a variable degree of fusion of its edges usually without calcification.<sup>3</sup> The effectiveness of balloon valvuloplasty in children and adolescents with congenital aortic valve stenosis has been clearly demonstrated.<sup>4,5,6,7</sup> Surgical valvotomy is associated with a high incidence of late (5 to 20 years) restenosis and aortic insufficiency.<sup>8</sup> Percutaneous balloon valvuloplasty is effective in children with congenital aortic stenosis, but not in adults with acquired calcific aortic stenosis. Valvuloplasty successfully reduces the peak systolic aortic gradient to the 20-40 mm of Hg range. Aortic insufficiency is produced in approximately 20% to 25% of patients but is mild in most of them. Vascular complications have been limited primarily to neonates and young infants and have diminished due to availability of small profile valvuloplasty catheters. Mortality is rare except among critically ill neonates and young infants. Follow up studies have documented early restenosis to be uncommon except in neonates and repeat balloon aortic valvuloplasty is often effective.<sup>9</sup>

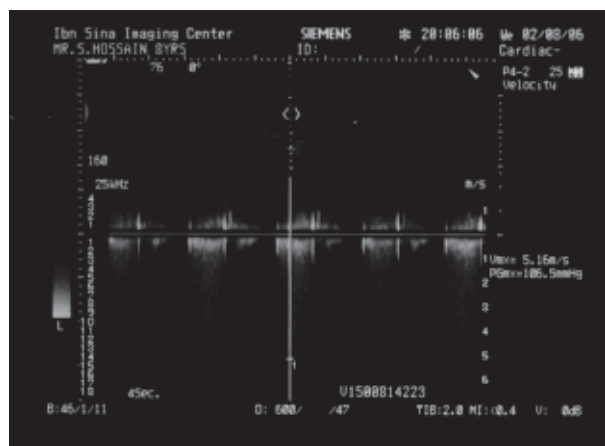
## Case Report:

A 8 years old boy of 124 cm height and 21 Kg weight presented with shortness of breathing, cough and palpitation of 6 months duration. His pulse was 70 per minute and blood pressure were systolic 70 mmHg, diastolic 35 mmHg. Examination of precordium showed normal first heart sound, soft second heart sound, ejection systolic murmur with thrill in the aortic area. Both lung fields were clear. Electrocardiogram showed right bundle branch block, with T inversion in lead V1 –V3, III, and aVF. Echocardiogram showed bicuspid aortic valve with severe aortic stenosis, peak systolic pressure



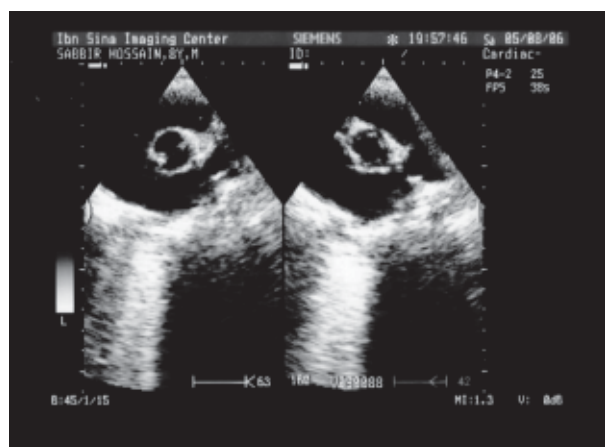
**Fig.-1:** Echocardiogram before PBAV showed bicuspid aortic valve with severe aortic stenosis (2<sup>nd</sup> August 2006)

**Address of Correspondence:** Dr A Q M Reza., Associate Professor of Cardiology, National Institute of Cardiovascular Diseases, Dhaka, Bangladesh.

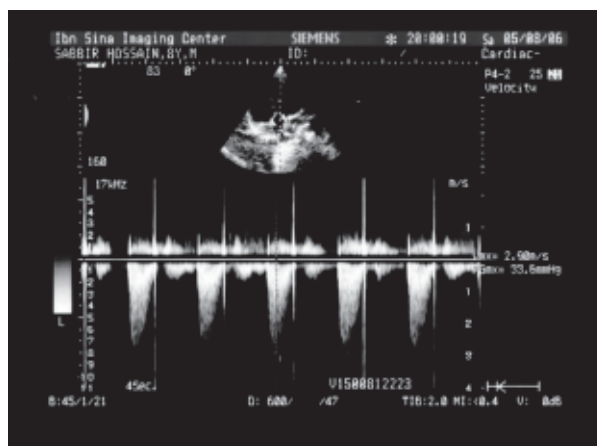


**Fig.-2:** Echocardiogram before PBAV showed peak pressure gradient across the aortic valve was 106.5 mm of Hg (2<sup>nd</sup> August 2006)

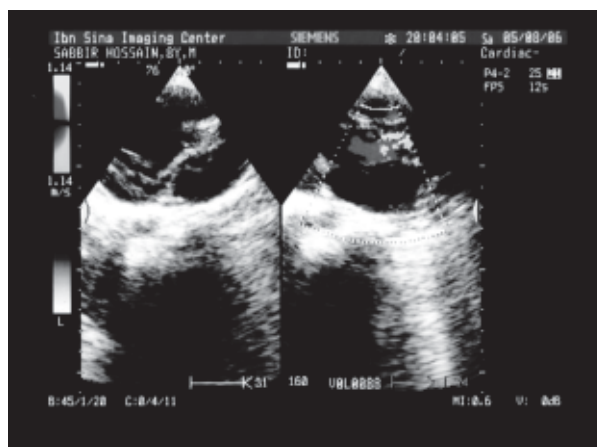
gradient across aortic valve 106.5 mm Hg, ejection fraction 67%, IVSTd 10 mm, LVPWd 10 mm, LVIDd 39 mm, LVIDs 25 mm, LA 27mm, AO 21 mm, ACS 09 mm and Aortic annulus 15 mm. There was mild concentric left ventricular hypertrophy with normal wall motion. Mildly thickened bicuspid Aortic valve with systolic doming of cusps present. Aortic balloon valvuloplasty was done on 3rd august 2006, with a 14 mm balloon. The balloon was advanced in a retrograde fashion across the aortic valve over a guide wire and was positioned approximately two-thirds of the way into the left ventricle. The balloon was then inflated by hand until the waist produced on the balloon by the valve disappeared. The balloon diameter chosen was 1 mm smaller than the diameter of the aortic valve annulus. Before procedure, aortic systolic pressure



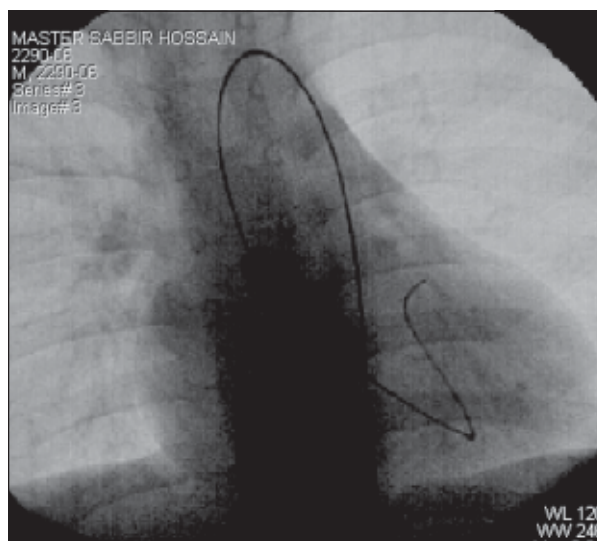
**Fig.-3:** Echocardiogram after PBAV showed bicuspid aortic valve with wide excursion of aortic valve during systole (5th August 2006)



**Fig.-4:** Echocardiogram after PBAV showed peak pressure gradient across the aortic valve was 33.6 mm of Hg (5th August 2006)



**Fig.-5:** Echocardiogram after PBAV showed aortic regurgitation grade -I (5th August 2006)



**Fig.-6:** One-Wire Technique for Performance of Balloon Aortic Valvuloplasty with 14 mm balloon (3rd August 2006)

was 100 mm Hg and left ventricular systolic pressure 270 mm Hg. After the procedure aortic systolic pressure was 120 mm Hg and left ventricular systolic pressure 148 mm Hg. Echocardiogram on 5th August 2006 showed, peak pressure gradient across aortic valve was 33.6 mm Hg, ejection fraction 71 %, IVSTd 10 mm, LVPWd 10 mm, LVIDd 39 mm, LVIDs 25 mm, LA 27mm, AO 21 mm, ACS 16 mm and left ventricular wall motion normal. Doppler study showed Aortic Regurgitation Gr. - 1 with trivial PR flow. Procedure was uneventful and he improved clinically with no haemodynamic complication. Patient was discharged two days after the procedure.

### Discussion:

In this case patient improved clinically and haemodynamically following procedure. His systolic blood pressure increased from 90 to 110 mmHg. Aortic cusp separation increased from 9 mm to 16 mm. Aortic systolic pressure increased from 100 mmHg to 120 mmHg. Left ventricular systolic pressure decreased from 270 to 148 mmHg. Pressure gradient across the aortic valve decreased from 170 to 28 mmHg immediately after the procedure. Echocardiographic peak pressure gradient across aortic valve decreased from 107 to 33 mm of Hg. Percutaneous balloon valvuloplasty is effective in children with congenital aortic stenosis without any significant complications like death, aortic regurgitation and femoral artery thrombosis or damage. The incidence of these complications correlate with the age of the child, the ratio of valvuloplasty balloon size and annular size, or both. Data from 204 children and infants who underwent aortic balloon valvuloplasty between 1982 and 1986, reported to the Valvuloplasty and Angioplasty of Congenital Anomalies Registry was reviewed and published in *Am J Cardiol* 1990. Valvuloplasty was successful in 192 of 204 children, reducing the peak systolic left ventricular ejection gradient from  $77 \pm 2$  to  $30 \pm 1$  mm Hg, ( p less than 0.001). The same degree of aortic stenosis gradient reduction was noted in both the 38 children under 1 year of age and in the 166 children over 1 year of age.<sup>4</sup> The data suggest that percutaneous balloon valvuloplasty provides effective acute relief of valvular aortic stenosis in both infants and children. Overseas experience has

shown that percutaneous balloon valvuloplasty can be done with little technical difficulty and excellent patient tolerance, resulting in good haemodynamic and clinical improvement and a low acute complication rate.<sup>10</sup> All this data suggest that percutaneous balloon valvuloplasty provides effective acute relief of valvular aortic stenosis in both infants and children.

In our case patient became asymptomatic, aortic valve area increased, aortic systolic pressure increased and transaortic pressure gradient decreased. Good result, lower cost, elimination of drawbacks of thoracotomy and cardiopulmonary bypass suggest, percutaneous balloon aortic valvuloplasty was the best treatment of choice for this patient with severe congenital aortic stenosis.

---

Conflict of Interest - None.

---

### Reference:

1. Friedman WF: Aortic stenosis. In Adams FH, Emmanouilides GC ( eds): *Heart Disease in Infants, Children, and adolescents*, 3rd ed. Baltimore, Williams &Wilkins, 1983:224.
2. Lababidi Z, Wu J, Walls JT. Percutaneous balloon aortic valvuloplasty: results in 23 patients. *Am J Cardiol*. 1984; 53(1): 194-197.
3. Wagner HR, Ellison RC, Keane JF, et al: Clinical course in aortic stenosis. *Circulation* 1977; 56 (suppl I ): 47-56.
4. Rocchini AP, Beekman RH, Ben Shachar G, et al: Balloon aortic valvuloplasty; results of the valvuloplasty and angioplasty of congenital anomalies registry. *Am J Cardiol* 1990; 65: 784-789.
5. McCrindle BW: Independent predictors of immediate results of percutaneous balloon aortic valvotomy in children. *Am J Cardiol* 1996;77:286-293.
6. Keane JF, Perry SB, L ock JE: Balloon dilatation of congenital valvular aortic stenosis. *J Am Coll Cardiol* 1990; 16:457-458.
7. Egito EST, Moore P, O' Sullivan J, et al: Transvascular balloon dilation for neonatal critical aortic stenosis: early and midterm result. *J Am Coll Cardiol* 1997; 29: 442-447.
8. Hsieh K, Keane JF, Nadas AS, et al: Long term follow up of valvotomy before 1968 for congenital aortic stenosis. *Am J Cardiol* 1086; 58: 338-341.
9. Robert H, Beekman III and Thomas R Lloyd: Balloon Valvuloplasty and Stenting for Congenital Heart Disease. In: Topol EJ ed. *Textbook of Interventional Cardiology*, 4<sup>th</sup> ed. Saunders an imprint of Elsevier, 2003; 962-968.
10. Ng KS, Tan AT, Chan CN, Ding ZP: Percutaneous balloon aortic valvotomy. *Singapore Med J*. 1993; 34(3): 208-210.