

Peripheral Vascular Stents in Clinical Practice

GMM Hossain

Department of Vascular Surgery, National Institute of Cardiovascular Diseases, Dhaka

Abstract :

Key words:

Peripheral vascular diseases, Vascular stents, Peripheral angioplasty

The development of endovascular stents has been a major advance in the treatment of vascular diseases. Endovascular interventions are quickly replacing bypass surgery and endarterectomy as the primary treatment options for stenotic peripheral arterial lesions. Studies using stents in the carotid and iliac arteries have shown acceptable clinical outcome. In this review the basic aspects of different stents are discussed.

(CVJ 2008; 1(1) : 81-83)

Introduction:

Stent Classification:

(Based on method of deployment and delivery)

1. Self-Expanding Stent
2. Balloon-Expanding Stent
3. Thermal-Expanding Stent

Self-Expanding Stent-

They are compressed within a delivery catheter and have a mechanical spring-like action. After insertion of the delivery system into the vessels the stents are expanded to their predetermined diameter after withdrawal of the sheaths.

Advantage-

High degree of flexibility

Easy to place

Smaller diameter delivery system

Less injuries & complications

Can be placed into tortuous arteries

Opposite iliac stenting is possible from a contralateral access site.

Disadvantage-

Marked Shortening after Expansion (Specially for Wallstent)

Low Radio-opacity

The Wallstent Endoprosthesis- most commonly used. Main indication is stenting of common iliac artery or external iliac artery occlusions. Gianturco Z-Stent- suitable for placement in large vessels.




Fig.-1: Wallstent².

Balloon-Expandable Stents-

Preloaded & compressed on an angioplasty balloon catheter before insertion. Once the stent is positioned at the appropriate site, the balloon is inflated to expand the metallic stent.

Advantage-

Early endothelialization

Can be re-inflated with a larger balloon, if needed.

Disadvantage-

Lacks longitudinal flexibility

Difficulty in negotiating tortuous vessels because of its rigidity

Larger diameter delivery system

Palmaz Stent- the most commonly used balloon-expandable stent for iliac artery occlusion. It is 316L stainless steel wire composed of 70% iron, 16-18% chromium, 10-4% Nickel, <2% manganese, 2-3% Molybdenum, <1% silicon and .03% carbon.

Strecker Stent- smaller diameter delivery system, radioopaque.

Wiktor Stent- use is limited to small vessels; delivered without a protective sheath.

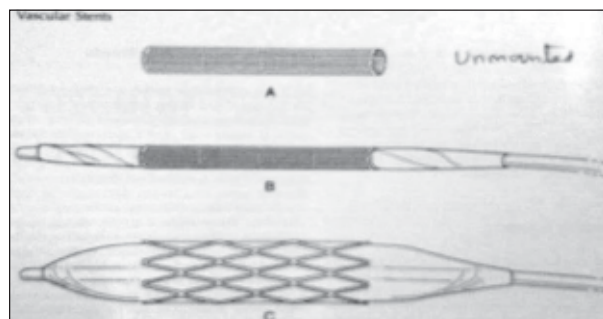


Fig.-2: Palmaz Stent²: A- unmounted, B- balloon mounted, C- Fully expanded

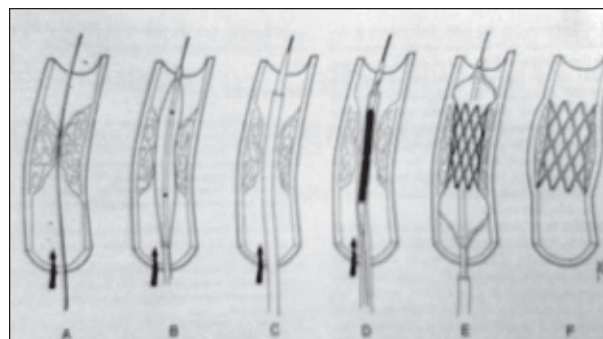


Fig.-3: Deployment Technique of self expanding stent- A- guidewire placed across the lesion, B- predilatation, C- sheath/dilator combination is advanced across the lesion, D- balloon/stent combination is placed, E- balloon inflation after retraction of the sheath, F- fully expanded stent in place²

Thermal-Expanding stents -

Dotter's group first proposed the concept in 1983. They are made up of nickel-titanium alloy, called Nitinol, which has unusual property of thermal memory. Above the transition temperature the stent recovers the predetermined shape

Examples of Thermal- Expandable Stents- Symphony nitinol Stent, Memotherm nitinol Stent, SMART Stent, Cragg Stent.




Fig.-4: Nitinol stent. (50% to 55% nickel and 45% to 50% titanium)³

Indications for Stents-

1. Occluded / Stenotic Atherosclerotic Lesions
2. Inadequate Angioplasty Results
3. Recurrence of stenosis
4. Venous Obstruction
5. Stent Grafts (Covered Stents)- used in cases of A-V fistula, arterial aneurysm & traumatic arterial injury

Contraindications-

1. Extravasation at Target Site
2. Densely Calcified Lesions
3. Severe Vessel Tortuosity

Discussion:

The development of endovascular stents has been a major advance in the treatment of vascular diseases. It offers less surgical trauma. Endovascular interventions are quickly replacing bypass surgery and endarterectomy as the primary treatment options for stenotic peripheral arterial lesions.⁴ Studies using stents in the carotid and iliac arteries have shown acceptable clinical outcome.⁵⁻⁷ Over the last few years, there has been some enthusiasm about the use of covered stent for femoro-popliteal obstructive lesions. Favorable outcome in terms of short and mid term patency and limb salvage has been reported by a number of groups.⁸⁻¹⁰ The advent of new materials will make these procedures simpler and safer as well as broaden their applications.

Conclusion:

Bypass surgery and endarterectomy are more cost effective than stenting in our setting. However, when a patient desires for stenting, we can provide him. In our clinical practice, a group of vascular patients are suitable for stenting. By this time, stents have been successfully placed in aorta, renal, iliac, femoral, popliteal, brachiocephalic, subclavian, carotid & -brachial artery. Now it is needed to extend awareness regarding peripheral vascular stenting among concerned physicians, surgeons as well as suffering patients.

Conflict of Interest - None.

References:

1. Carrel A : Results of the permanent intubation of the thoracic aorta. *Surg Gynecol Obstet* 1912;15: 245-248.
2. Murthy V, Shah H, & Dalsing MC. Intravascular Stents. In White RA, Fogarty TJ (ed). *Peripheral Endovascular Interventions*. New York, Springer-Verlag 1999: 321-351.

3. Song M, Rodino W, Wisselink W, & Panetta TF. Vascular Stents. In Moore WS, Ahn SS (ed). Endovascular Surgery. Pennsylvania, W.B. Saunders Company, 2001: pp70-86.
4. Kudo T, Chandra FA, Kwun WH, Haas BT, Ahn SS. Changing pattern of surgical revascularization for critical limb ischemia over 12 years: endovascular vs. open bypass surgery. 2006; 44(2): 304-13.
5. Pieniazek P, Musialek P, Kablak-Ziembicka A, Tekieli L, Motyl R, Przewlocki T, Moczulski Z, Pasowicz M, Sokolowski A, Lesniak-Sobelga A, Zmudka K, Tracz W. Carotid Artery Stenting with Patient- and Lesion-Tailored Selection of the Neuroprotection System and Stent Type: Early and 5-Year Results From a Prospective Academic Registry of 535 Consecutive Procedures (TARGET-CAS). *J Endovasc Ther.* 2008; 15(3): 249-62.
6. Bush RL, Kougiaris P, Guerrero MA, Lubbe DF, Zhou W, Lumsden AB, Lin PH. A comparison of carotid artery stenting with neuroprotection versus carotid endarterectomy under local anesthesia. *Am J Surg.* 2005; 190(5): 696-700.
7. Surowiec SM, Davies MG, Eberly SW, Rhodes JM, Illig KA, Shortell CK, Lee DE, Waldman DL, Green RM. Percutaneous angioplasty and stenting of the superficial femoral artery. *J Vasc Surg.* 2005; 41(2): 269-78.
8. Saxon RR, Coffman JM, Gooding JM, Ponc DJ. Long-term patency and clinical outcome of the Viabahn stent-graft for femoro-popliteal artery obstructions, *J Vasc Interv Radiol.* 2007; 18(11): 1341-9.
9. Ihnat DM, Duong ST, Taylor ZC, Leon LR, Mills JL Sr, Goshima KR, Echeverri JA, Arslan B. Contemporary outcomes after superficial femoral artery angioplasty and stenting: the influence of TASC classification and runoff score. *J vasc surg* 2008; 47 (5) : 967-74.
10. Kedora J, Hohmann S, Garrett W, Munschaur C, Theune B, Gable D. Randomized comparison of percutaneous Viabahn stent grafts vs prosthetic femoro-popliteal bypass in the treatment of superficial femoral arterial occlusive disease. *J Vasc Surg.* 2007; 45(1): 10-6.