

Case Reports

Ventricular Septal Defect as a Complication of Blunt Chest Trauma: A Rare Occurrence and First Case-Report in Bangladesh

AW Chowdhury, AQM Reza, MA Baqui, MA Muttalib, MS Tanveer, SA Islam, MS Ullah, DK Mondal, SS Islam, MS Shahidullah, AHM Kamal

Department of Cardiology, National Institute of Cardiovascular Diseases, Dhaka.

Abstract:

Key words:
Ventricular septal defect, Blunt chest trauma.

Traumatic ventricular septal defect (VSD) is a very uncommon condition, especially in association with blunt chest trauma. A healthy young adult was diagnosed as a case of VSD one week after a road-traffic accident. History and other medical records suggest it was an acquired post-traumatic VSD. Thus, all patients of blunt chest trauma deserve close cardiac evaluation.

(CVJ 2008; 1(1) : 105-108)

Introduction:

Cardiac injuries from blunt chest trauma are usually the result of high speed motor vehicle accidents. Cardiac injuries result in 20% of such accidents. The severity of external injuries does not necessarily reflect the severity of cardiac trauma. Blunt chest trauma can cause a variety of cardiac injuries such as myocardial contusion, myocardial rupture, pericardial trauma, valvular disruption and acute myocardial infarction.¹ We report a case of traumatic rupture of the interventricular septum caused by a non-penetrating chest trauma.

Case report:

Mr. Kawsar, a 25 year old Bangladeshi student had a road-traffic accident in Russia one year back when he was driving his car. His car collided with another car coming from opposite side. He suffered a violent crash with multiple injuries all over his body. He had blunt trauma on his chest from the steering wheel of the car which itself was broken. He was treated in ICU in Kursk hospital. One week later, he was apparently improved and discharged from hospital. With gradual ambulation on the second day at home he became short of breath, which began worsening in severity over the next few days.

He was readmitted in the same hospital and was diagnosed as a case of congestive cardiac failure (CCF) due to ventricular septal defect (VSD) with

tricuspid regurgitation. He was advised for surgical closure of VSD, but due to high expenditure he could not afford to undergo operation in Russia and returned to Bangladesh.

Immediately after returning home, he was admitted in National Institute of Cardiovascular Diseases (NICVD), Dhaka with the complaints of shortness of breath and swelling of whole body. On examination, he was dyspnoeic, anasarca was present, JVP was raised, liver was enlarged and tender. There was a pronounced precordial systolic thrill along with a loud 5/6 pansystolic murmur in the left parasternal area radiating from left to right. He was diagnosed as a case of ventricular septal defect / rupture with congestive cardiac failure (CCF). He was treated conservatively with intravenous diuretics, inotropes, ACE inhibitor and antibiotics.

Echocardiography was performed and showed there was right sided volume overload, a muscular VSD with left to right shunt and severe tricuspid regurgitation (TR). The ventricular septal defect traversed the interventricular septum (IVS) spirally and obliquely with one opening towards apical IVS in LV side and the other opening towards RV side below septal leaflet of tricuspid valve producing distortion of the tricuspid leaflet.

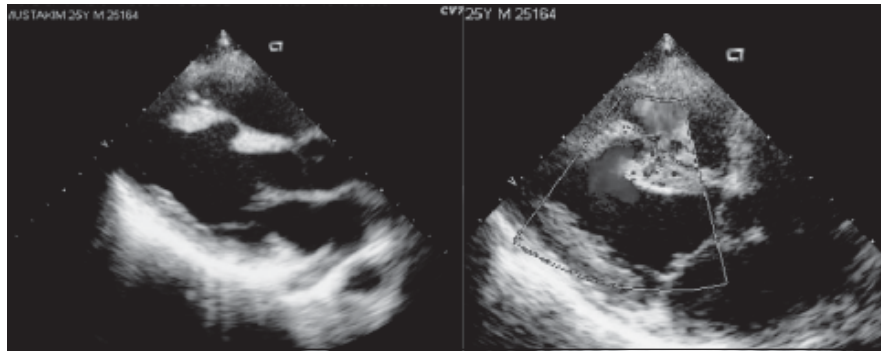


Fig.-1: Parasternal long axis view showing dissection of muscular septum (2-D image -left) and CFM (colour flow mapping) showing left to right shunt across VSD (right).

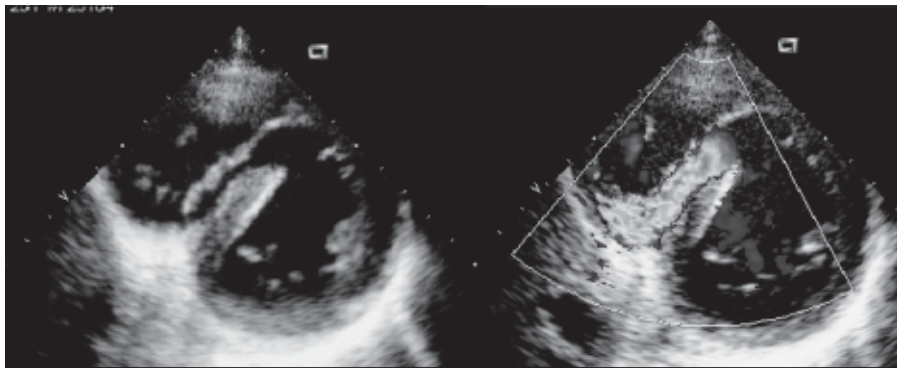


Fig.-2: Parasternal short axis view showing spiral communication through IVS (2-D image-left) and CFM showing left to right shunt (right).

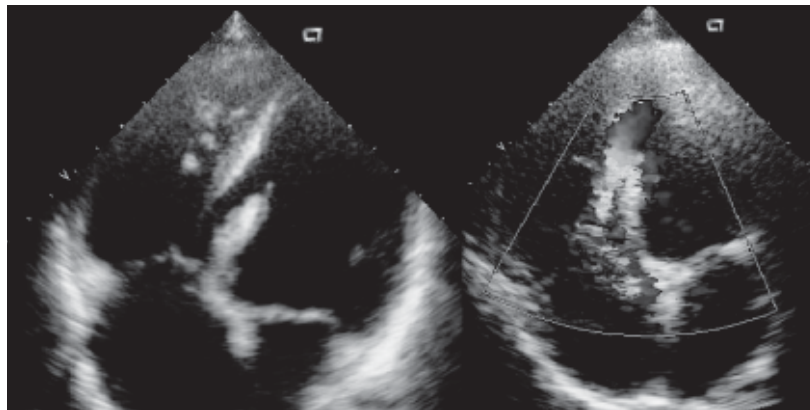


Fig.-3: Apical 4-chamber view showing oblique muscular VSD and dilated RA and RV (2-D image- left) and CFM showing left to right shunt with TR (right).

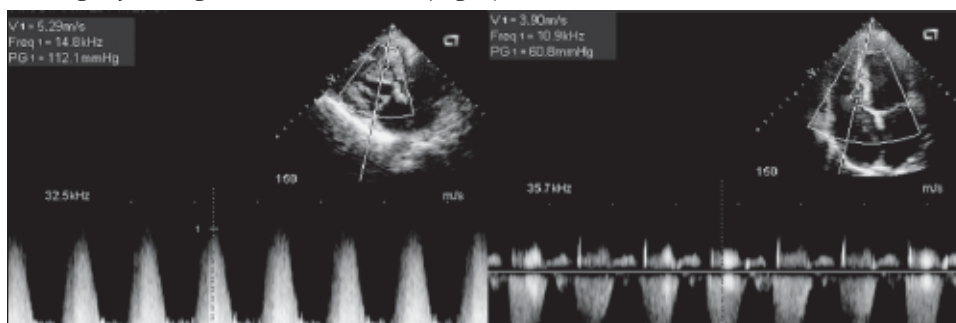


Fig.-4: 2-D and CFM guided CW-Doppler in parasternal long axis (left) and apical 4-chamber (right) view showing high gradient Doppler signal across VSD.

Mr. Kawsars's ECG showed RBBB with tachycardia. Chest radiography showed linear fracture of the left 7th rib, cardiomegaly and bilateral hilar congestion. There was polymorphonuclear leucocytosis, but blood culture revealed no growth. Cardiac catheterization showed normal coronaries and VSD with significant left to right shunt. The patient was then referred for surgical correction VSD with repair of tricuspid valve.

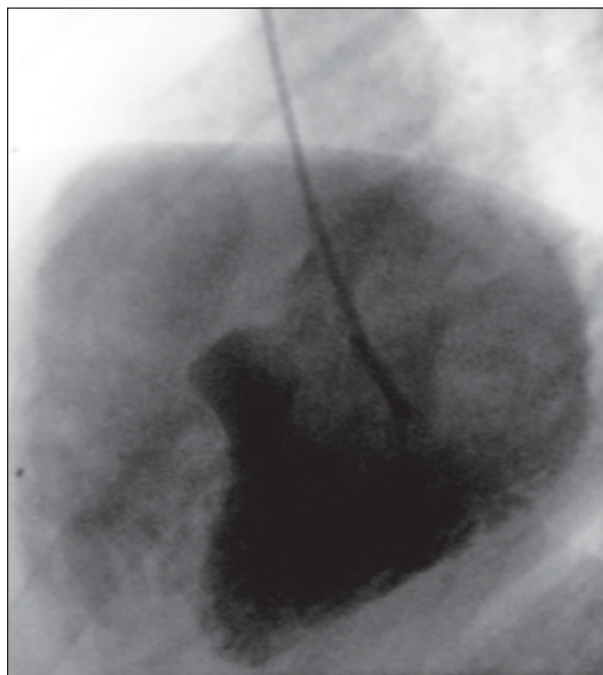


Fig.-5: LV graphy shows contrast passing from LV to RV through oblique muscular VSD.

Mr. Kawsar came of an upper middle-class family and suffered no major acute or chronic illness since his childhood. His growth, development, education and social interactions were sound and normal. All of his examination and investigation reports were normal before his departure to Russia. As there was no evidence of congenital VSD and the symptoms started after the road-traffic accident, the VSD with TR in this patient was diagnosed as of traumatic origin due to blunt chest trauma.

Discussion:

Cardiac injuries from blunt chest trauma are usually the result of high speed motor vehicle accidents. The severity of external injuries does not necessarily reflect the severity of cardiac trauma. Blunt chest trauma can cause a variety of cardiac injuries such as myocardial contusion, myocardial

rupture, pericardial trauma, valvular disruption, aneurysmal dilatation of IVS, RV dysfunction and acute myocardial infarction. Myocardial contusion is the most frequent cardiac injury following blunt chest trauma and occurs in 16-76% patients involved in motor vehicle accidents.²

Interventricular septal rupture, especially when isolated, is extremely rare. In 1958, Parmley et al.³ reviewing 5467 cases of blunt chest trauma reported five cases of isolated VSD. The isolated rupture of the IVS following blunt chest trauma was first reported by Hewett in 1847.⁴

The previous reports support that traumatic VSD occurs commonly in young male.⁵ Common site of involvement is muscular part of IVS and the septum near the apex being the most common site of rupture.³ Other sites are membranous part, between right atrium and left ventricle⁵, or even infundibular septum.⁶

Rupture of the IVS may occur almost immediately after injury or many days later.¹ The lesion is believed to occur because the heart is compressed between the sternum and the spine or as result of extreme intra-thoracic pressure during sudden deceleration.⁴ The septal rupture is also considered to occur due to compression of the interventricular septum in end-diastole (immediately following atrial contraction) or during isovolumetric systole, when the cardiac valves are closed and the ventricles are filled with blood.⁵

In our patient, VSD was muscular and spiral in morphology which supports the role of blunt chest trauma, because intense pressure of closed trauma caused splitting of septum through muscle plane. In other words, blunt dissection occurred through IVS due to external compressive force and internal resistance by noncompressible blood.

Parmley et al. postulate that septal injury causes initial oedema, followed by liquefaction necrosis and appearance of true defect. This sequence of events could explain the delay in the occurrence of the septal defect.³ This may be the mechanism in our case as the occurrence of symptoms of VSD started one week after the initial incidence.

Another probability of VSD is post-traumatic myocardial infarction which usually occurs two to three days later following infarction.⁷ The mechanism of myocardial infarction following blunt

chest trauma may be related to an intimal tear of the coronary artery with thrombosis, coronary spasm, coronary embolism, myocardial contusion or aortic dissection involving the coronary artery, atherosclerosis.¹ In this case, there is no wall motion abnormality on echocardiography and coronary angiogram revealed no occlusive lesion. So, myocardial infarction is not the cause of VSD in this case.

The atrio-ventricular septum, a small area of the membranous portion of the ventricular septum that separates the left ventricle from the right atrium, is in close proximity to the septal tricuspid, the aortic sinus and the atrio-ventricular conduction system. This intimate relationship explains the usual involvement of one or more of these structures on traumatic lesions of atrio-ventricular septum.⁵ In our case, tricuspid valve injury and right bundle branch block can be explained by this mechanism.

Conclusion:

Ventricular septal defect is a rare but possible complication after blunt chest trauma. It can occur even after several days following trauma. Therefore, patients with blunt chest trauma require systematic

monitoring of cardiac function to enable timely diagnosis and treatment.

References:

1. Genoni M, Jenni R, Turina M. Traumatic ventricular septal defect. *Heart* 1997; 78: 316-8.
2. Fang B, Li C. Acute myocardial infarction following blunt chest trauma. *Eur Heart J* 1994; 15: 705-7.
3. Parmley L, Manion W, Mattingly T. Non-penetrating traumatic injury of the heart. *Circulation* 1958; 18: 371-96.
4. Evora P, Ribeiro P, Brasil J, Otaviano A, Amaral F, Reis C, et al. Late surgical repair of ventricular septal defect due to nonpenetrating chest trauma: review and report of two contrasting cases. *J Trauma* 1985; 25: 1007-9.
5. Amorim MJ, Almeida J, Santos A, Bastos PT. Atrioventricular septal defect following blunt chest trauma. *European Journal of Cardio-thoracic Surgery* 1999; 16: 679-82.
6. Pierli C, Ladanza A, Pasqua AD, Sinicropi G. Unusual localization of a ventricular septal defect following blunt chest trauma. *Heart* 2001; 86; 6-doi: 10.1136/heart.86.1.e6.
7. Selzer A, Gerbode F, Kerth W. Clinical, haemodynamic and surgical considerations of rupture of the ventricular septum after myocardial infarction. *Am Heart J* 1969; 78: 598-604.